51years		Vent. rate	86 bpm	Normal sinus rhythm with sinus arrhythmia
Male	Caucasian	PR interval	152 ms	Anteroseptal infarct, possibly acute
		QRS duration	80 ms	** ** ACUTE MI ** **
Room: ER		QT/QTc	338/404 ms	Abnormal ECG
		P-R-T axes	57 -4 32	

Technician: PJC
Test ind: CHEST PAIN
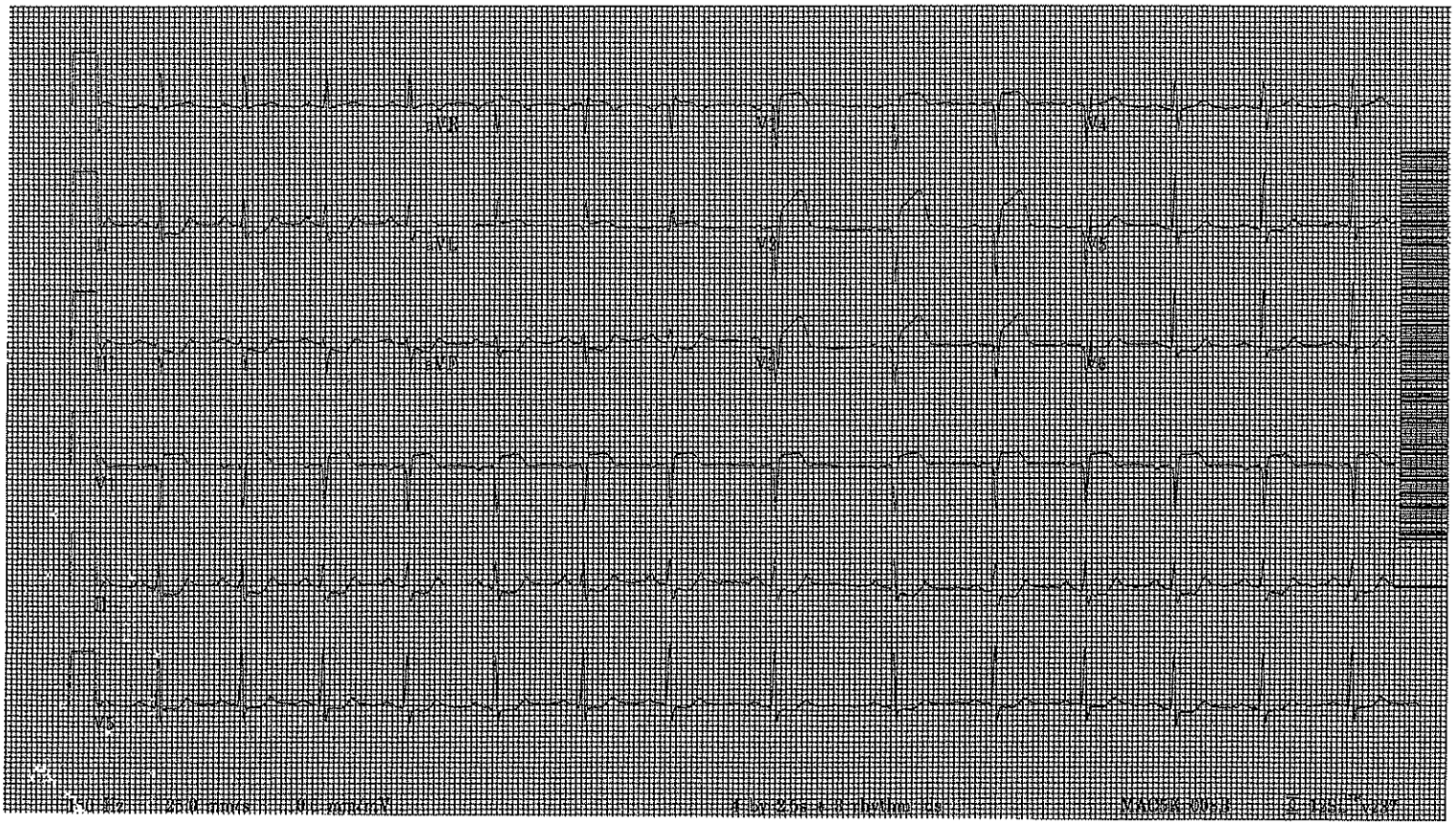
Referred by: Unconfirmed